

Canine Tactical Field Care

Part Three –

Thoracic and Abdominal Trauma

Wesley M. Taylor, DVM, Diplomate, ACLAM

Part One: Physical Examination and Medical Assessment of the Canine Patient was in Vol 8 Ed 3, Summer 08.

Part Two: Massive Hemorrhage Control and Physiologic Stabilization of the Volume Depleted, Shock-Affected or Heatstroke-Affected Canine Patient was in Vol 9 Ed 2, Spring 09.

Part Four: Gastric Dilatation and Volvulus, Other Gastrointestinal Disturbances and Toxicoses and

Part Five: Common Orthopedic and other Traumatic Injuries will be in upcoming editions of the JSOM.

ABSTRACT

Military and law enforcement agencies have seen a dramatic increase in the utilization of working canines both at home and in foreign deployments. Due to the fact that professional veterinary care is sometimes distant from internal disaster or foreign deployment sites, the military medic, police tactical medic, or other first-response medical care provider may be charged with providing emergency or even basic, non-emergency veterinary care to working canines. (*Editor's Note: Military veterinary detachments are collocated next to the major human treatment facilities in a deployment environment. In a deployed environment veterinary care is located in areas where they are most needed or where most of the animals are located.*) The medical principles involved in treating canines are essentially the same as those for treating humans, but the human healthcare provider needs basic information on canine anatomy and physiology and common emergency conditions in order to provide good basic veterinary care until a higher level of veterinary care can be obtained. This article represents the third in a series of articles designed to provide condensed, basic veterinary information on the medical care of working canines, to include military working dogs (MWDs), police canines, federal agency employed working canines, and search and rescue dogs, to those who are normally charged with tactical or first responder medical care of human patients. This article provides an overview of the diagnosis and treatment of common traumatic injuries to the thorax and abdomen.

BACKGROUND AND PURPOSE

The recent upsurge in the use of working canines as a result of the continuing Overseas Contingency Operation (formerly the Global War on Terror) has resulted in a need for more veterinary healthcare providers in the field setting.¹⁻⁶ The canine is a critical member of the tactical team or the search and rescue team, and it is susceptible to similar injuries and conditions as its human colleagues. Whether deployed overseas in support of military missions or at home in support of terrorism events or natural disasters, working canines may become casualties. In some cases, these canines are injured when definitive veterinary care is not immediately available,^{4,6-9} especially in cases such as natural disasters or small distantly deployed units where it is simply not feasible to have a veterinarian on site with each canine team. Professional veterinary care may be hours to days away from the location of the injured canine, and providing veterinary care frequently falls to the dog handler, combat medic, or other human healthcare provider.^{4,6-9} For this rea-

son, it is critical that non-veterinary healthcare providers be trained in basic veterinary medical skills to allow them to stabilize a critically injured working canine in the field in order to safely transport to definitive veterinary care, therefore enabling a more expeditious return to duty.

(*Editor's Note: Veterinary personnel have been located in 15 to 17 different locations in Iraq during 07-09. If kinetic force was planned for a certain area, they moved a jump team in that area to cover expected injuries. This jump team included a veterinarian. Downrange commanders state that "With over 650 dogs in theater, it is true that there can never be a veterinarian with each team, even SOF doesn't provide this to their teams. However, engineer MDD units have slots for one 68T/6 teams. OIF currently has eight vet clinics and two additional sites with 68Ts available 24/7. Therefore, first-responder care has been integrated into handler training for the past five years and, although transport to definitive vet care is necessary, catastrophic wounding certainly does not occur at a rate that exceeds our capacity."*)

The purpose of this article is to introduce and familiarize the tactical medic and other human health-care providers with some of the more common canine thoracic and abdominal conditions experienced in traumatic injuries. The article presents radiographs of normal canine anatomy (Figs. 1 and 2) for illustration, and includes radiographs of some pathological conditions for discussion and illustration of the anatomical and physiological abnormalities associated with canine trauma (Figs. 3-10). It discusses assessment and treatment of these conditions. It is beyond the scope of this article to instruct in the complete diagnosis of abdominal and thoracic trauma versus differential conditions. However, by studying this overview, the reader with general knowledge of emergency medicine and surgery should be able to familiarize himself with these conditions and perform early medical assessment of the canine trauma patient⁹. (*Editor's Note: Part of the purpose of this article is to familiarize physician / surgeons with canine care in the event they are called upon to provide emergency care to a working dog in the absence of a licensed veterinarian. As stated in the article, this absence of professional veterinary care may last for days, and in such an instance it is theoretically possible that a physician surgeon could be called upon to serve as a veterinarian and provide diagnosis and surgical care.*) It is the express purpose of this article to provide some baseline veterinary guidance to human healthcare providers who may be forced to perform these interventions in the absence of direct veterinary participation. In some instances, radiology and surgery could be feasible to save the life of a canine prior to the availability of professional veterinary help.

As mentioned in prior articles in this series, it is critical for the care provider to ensure a safe treatment environment by placing a muzzle on the canine patient prior to any treatment attempts.^{8,10} (*Editor's Note: One critical thing that needs to be mentioned is to be aware of where the closest veterinary facility/hospital to your location is and to establish phone contacts with that veterinarian in case of emergency. That will be a major tool in the preparation of canine emergency care and the survival of a critically injured patient. There are times that dogs have been operated on or emergency procedures conducted because it was something they felt they could do, but they are not licensed to do them, and in fact, a veterinarian was only five or ten minutes away. It should be emphasized that if a veterinarian is not on site, then after initial stabilization, or sometime during stabilization, all efforts should be made to contact a veterinarian for further recommendations. Most veterinarians are a phone call away, but of course in a combat situation, communication would be limited. If you are anywhere by radiograph equipment, a phone should be available.*)

THORACIC TRAUMA

Thoracic trauma is commonly encountered as a result of both blunt and penetrating injury. In the military and police operational environment, penetrating in-

juries to the thorax from ballistic wounds and explosions are relatively high incidence injuries.^{6,9} Ballistic wounds account for approximately half of the life-threatening or fatal wounds incurred by military working dogs in Afghanistan and Iraq, with explosive blast injuries accounting for the majority of the other half.⁹

Wounds to the thorax from any cause (in relation to wounds to other parts of the body) appear to be more common in canines than in human servicemembers.⁹ Pneumothorax, hemothorax, pulmonary contusion, diaphragmatic rupture, and rib fractures are among the thoracic injuries in working and non-working canines.^{9,11}

Physical examination findings from the canine patient can provide important clues as to the nature of the thoracic injury. A primary visual and palpation survey of the chest and neck will immediately reveal external evidence of trauma in flail chest, sucking chest wound, and massive external hemorrhage cases, but some penetrating injuries will present with small, minimally bleeding wounds that are only detectable after the chest has been shaved.¹³ The heart and lungs should be auscultated and the rate and quality of heart and lung sounds in all quadrants of the thorax should be assessed. The clinician should note and monitor respiratory rate, pattern, and effort every few minutes over the treatment period. For comparison, Table 1 presents normal physiological parameters for the working canine.

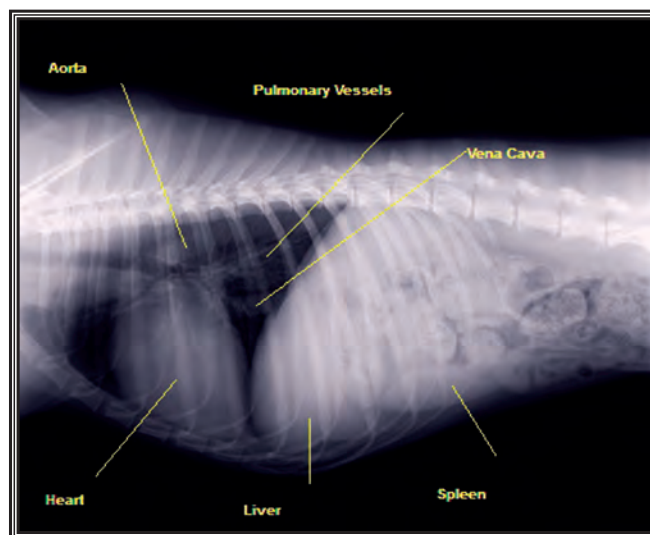


Figure 1

NORMAL ANATOMY

The thoracic cavity in the canine patient occupies the cranial 40-50% of the dogs' trunk between the thoracic limbs and the pelvic limbs (Fig. 1). There are 13 ribs in the canine patient, with the first 12 ribs being attached to the sternum via cartilaginous extensions and the 13th rib "floating" free of sternal attachment. The diaphragm separates the abdominal cavity from the thoracic cavity as it does in the human patient, coursing diagonally dorso-caudal from its ventral attachment to

the sternum at approximately the 7th rib to its tapered tips at the 12th to 13th rib, with the crura extending to their dorsal attachments at the L3-L4. The heart occupies the ventral 60-70% of this space, from approximately the 4th to the 7th rib; it sits with its apex against the sternum and the base positioned dorsally and tilted slightly cranial. When viewed from a ventro-dorsal orientation, the heart is positioned in the center of the thorax, abutting the diaphragm, with a normal “bulge” representing the right atrium protruding cranio-laterally (Fig. 2). The mediastinum is visible cranial to the heart on radiographs (Figs. 1 and 2) and is usually approximately one-third the width of the cardiac silhouette.

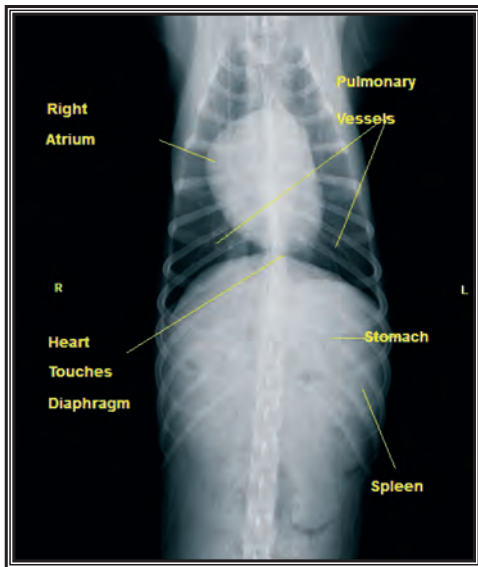


Figure 2

All dogs have a relatively V-shaped thorax when viewed from the head or tail, with the dorsal aspect of the rib cage being substantially wider than the ventral aspect. However, this anatomical shape is particularly pronounced in “deep-chested” dogs, such as German Shepherds and large-framed Labrador Retrievers, and is thus the common thoracic anatomy in most military and police working dogs. The lungs are predominantly situated in the dorsal 50% of the thoracic cavity, with thinning points of the lung lobes extending ventrally into the space between the heart, mediastinum, and ribs. Because the lungs have significantly more available volume in the dorsal aspect of the thorax, the sternal position (standing or sitting sternally), where the lungs can float dorsally upon thoracic fluid or displaced organs, is most comfortable for canines experiencing respiratory distress. The pulmonary vasculature is normally visible radiographically in each quadrant of the thorax (Figs. 1 and 2).

PNEUMOTHORAX

Pneumothorax, or air in the pleural space, occurs commonly secondary to thoracic trauma. Two types of pneumothorax are recognized: pneumothorax and tension pneumothorax. Pneumothorax (non-tension)

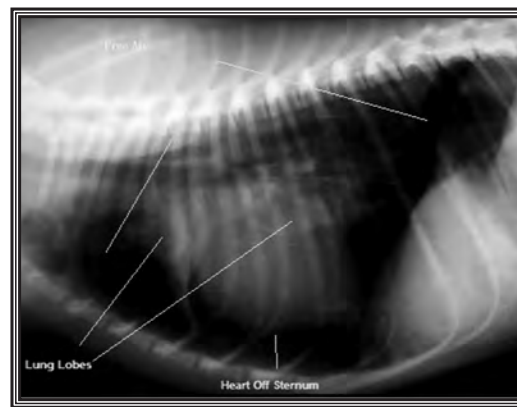


Figure 3

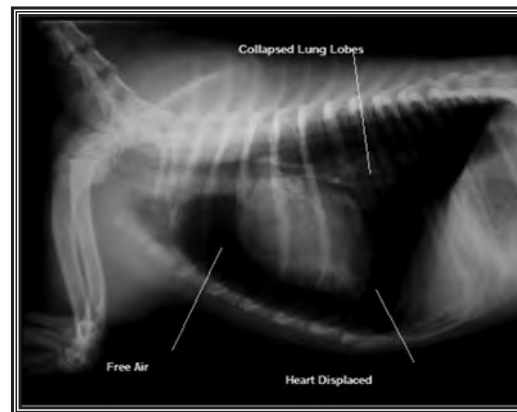


Figure 4

occurs in instances where air enters the pleural space during inspiration, but the air is able to escape the chest, such as through a traumatic hole in the thoracic wall (sucking chest wound) during expiration. Tension pneumothorax is generally the result of sharp penetrating trauma, where intrathoracic pressure increases with inspiration, but the air brought into the thoracic cavity cannot escape in expiration.¹²

In cases of pneumothorax or open pneumothorax, diagnosis is based upon physical exam findings and radiographs where available. Auscultation of the thorax typically reveals quiet or absent lung sounds relative to the degree of respiratory effort. (*Editor’s Note: Muffled heart sounds should also be included in auscultative abnormalities, as well as characteristics of the breathing pattern [rapid shallow, restrictive].*) The practitioner may notice open wounds to the thorax, including severely displaced rib fractures or open wounds in the intercostal spaces. Signs of pneumothorax on thoracic radiographs include a cardiac silhouette that is raised off of the sternum, collapsed lung lobes, free air in the pleural space (Figs. 3 and 4), and loss of pulmonary vascular markings near the periphery (Figs. 5 and 6). Initial treatment of the open pneumothorax includes cleaning and disinfection of the wound and placement of an air-impermeable bandage or chest seal over the wound. It is the author’s observation that the hair on the canine thorax can make chest seal placement difficult, but seals can be held in place by circumferential

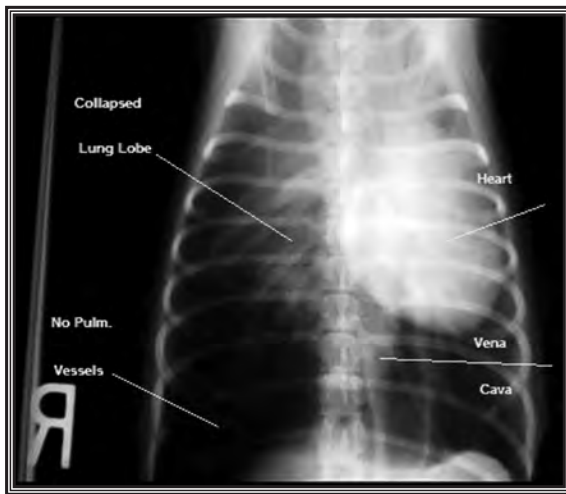


Figure 5

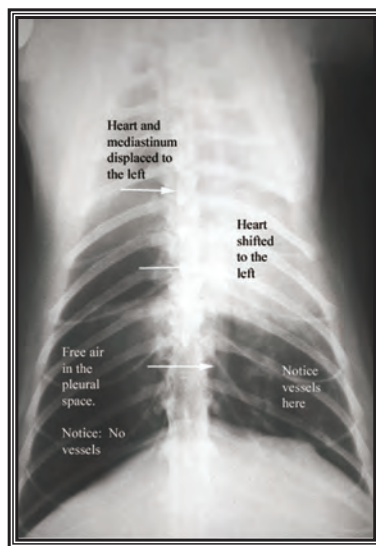


Figure 6

bandaging around the thorax. It is important for the care provider to remember two potential complications of chest bandaging: restriction of respiratory ability and the potential for creation of a tension pneumothorax in trauma patients.¹³ Positioning of the patient is as important in canine thoracic injuries as it is in humans. Canine patients with respiratory difficulty are usually most comfortable sitting or standing in a sternal position, with the dorso-ventral axis of the dog perpendicular to the ground.^{11,12}

Tension pneumothorax results in a patient who may or may not have obviously significant thoracic wounds, but who expresses progressively deteriorating respiratory distress. As pressure increases in the affected hemithorax, the mediastinum along with the heart and great vessels is displaced toward the opposite hemithorax. This displacement is visible radiographically (Figs. 5 and 6). Physical examination findings include any evidence of trauma to the chest (or possible trauma), progressively deteriorating cardiovascular status as heart function, deteriorating respiratory distress,

and diminishing to absent lung sounds on the affected side. Diagnosis can be confirmed in the field by the preferred presumptive treatment: placement of a 14 gauge needle or IV catheter into the affected hemithorax. In the canine patient, the catheter should be passed intercostally in the 7th to 9th rib spaces of the dorsal one-third of the thorax, with the needle oriented perpendicular to the skin and pointing toward the opposite hemithorax.^{11,12}

It is important for the canine emergency care provider to recognize that the clinical signs of tension pneumothorax (increasing respiratory distress, cardiovascular collapse) can be very similar to those of gastric dilatation and volvulus (GDV) in the working canine. This occurs as a result of similar underlying physiological abnormalities including diminished hemodynamic return via the great veins and reduction of the available lung volume by expanding pressure in the thoracic cavity. These two conditions can be distinguished clinically by the continuance of lungs sounds in both hemithoraces in GDV patients and by the palpable presence of the air-distended stomach in the abdomen.

Treatment of pneumothorax varies according to severity. In cases of penetrating trauma to the thorax, radiographic evaluation is indicated as soon as feasible. Sucking chest wounds, penetrating injuries to the chest, and some cases of closed pneumothorax will require emergency surgical thoracotomy and repair.^{11,12}

FLAIL CHEST

Flail chest is a condition in which individual ribs are broken in at least two places, resulting in a panel of chest wall that moves paradoxically (moving in on inspiration and out on expiration) during the breathing cycle.¹⁴ Medical management of flail chest includes placing the dog in lateral recumbency with the injured (flail segment) side down and bandaging as indicated. Surgical repair is eventually indicated in these cases,¹⁴ but for patients who are stable and have no concurrent pneumothorax or hemothorax, this repair should be delayed until professional veterinary surgical care is available.

PULMONARY CONTUSION

Pulmonary contusion is one of the most common complications of thoracic trauma, and can range in severity from mild to life threatening. Radiographic evidence of pulmonary contusion can range from interstitial to severe alveolar pulmonary patterns. Harsh lung sounds are often auscultated on physical examination. Treatment for pulmonary contusion varies according to severity. In mild cases of pulmonary contusion no specific treatment is required. More severely affected patients may require oxygen support and in some cases, mechanical ventilation. As in all trauma patients, treatment for shock should be initiated immediately to restore perfusion. However, in the presence of pulmonary contusion, aggressive fluid therapy may lead to worsening of

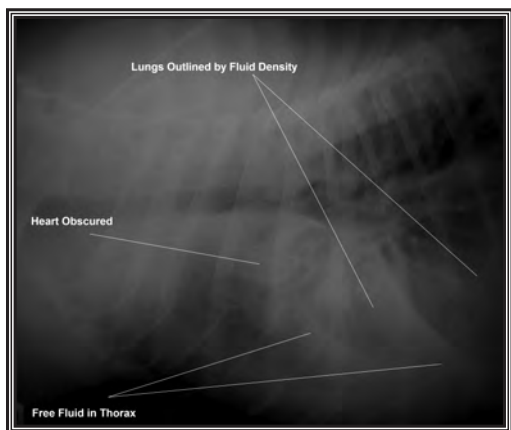


Figure 7

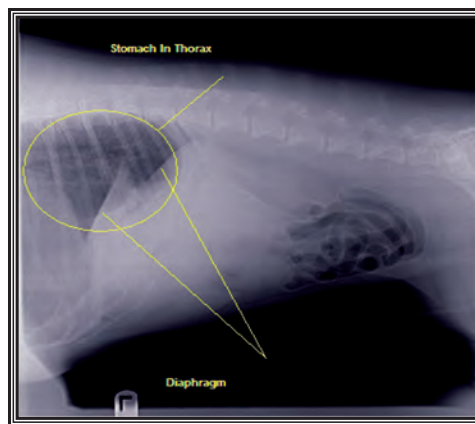


Figure 8

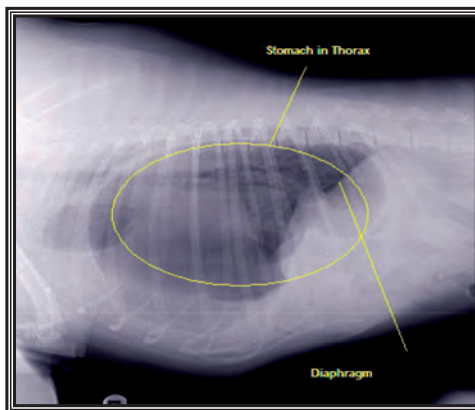


Figure 9

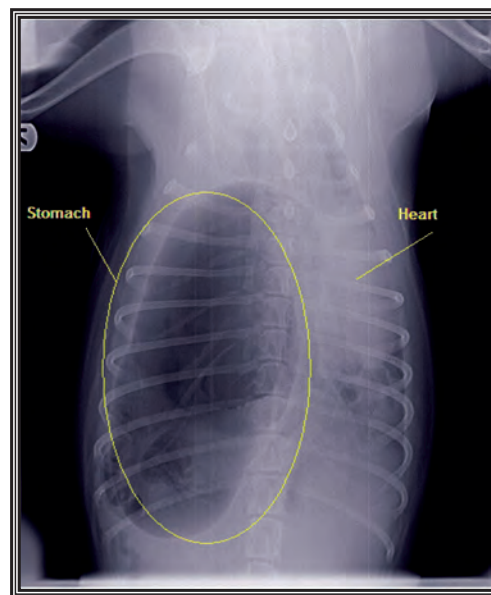


Figure 10

the respiratory status and excessive fluid administration should be avoided. Pulmonary contusion may worsen in the first 24 to 48 hours following a traumatic event and resolves over four to seven days. The presence of pulmonary contusion does not automatically warrant antibiotic therapy, and diuretics are generally not indicated.^{11,14}

HEMOTHORAX

Hemothorax will result in changes in cardiac and pulmonary physiology that are detectable on physical examination. As blood starts to accumulate in the thoracic cavity, it will go to the most dependent part of the chest, which is the ventral thorax on a dog sitting sternally or standing. Fluid in the thoracic cavity can muffle heart and lung sounds and the care provider might be able to detect a fluid line via auscultation of lung sounds and percussion (tapping while auscultating) of the thorax. As blood loss into the thoracic cavity increases, the canine will begin to exhibit clinical signs of blood loss, but without the clinical evidence of bleeding. Thus, signs of cardiovascular shock and blood loss with a rising fluid line are the clinical diagnostic indicators of hemothorax. When plain radiographs are available, the care provider will find evidence of pleural fluid in the ventral aspect of the thorax and obscuring of the cardiac silhouette on lateral views (Fig. 7) and the caudal and lateral aspects of the thorax on ventro-dorsal views. (*Editor's Note: Thoracocentesis would also be diagnostic and therapeutic in these cases. Diagnosis of worsening hemothorax is an indicator for immediate emergency exploratory thoracotomy.*^{11,12})

DIAPHRAGMATIC RUPTURE / HERNIA

Diaphragmatic rupture or hernia is not an uncommon result of thoracic and / or abdominal trauma in the canine patient. Displacement of part of or entire abdominal organs is common in large diaphragmatic hernias, including potential displacement of intestines, stomach, spleen, liver, omentum, or kidney(s). Small diaphragmatic ruptures can be difficult to diagnose clinically as they do not always result in the typical clinical

signs of respiratory distress, abdominal splinting and pain, and vomiting or diarrhea. Displacement of the entire stomach into the thorax can result in gas distension of the stomach within the thoracic cavity and clinical mimicry of a tension pneumothorax (Figs. 8, 9, and 10). In many cases, radiographs are required for diagnosis of the canine diaphragmatic trauma. Emergency surgical repair of the hernia and associated pathology is indicated in diaphragmatic trauma cases.^{11,12} (*Editor's Note: Emergent repair required for gastric displacement. Di-*

aphragmatic hernias have a higher morbidity and mortality if surgical intervention is performed within 24 hours of the trauma. Gastric displacement although emergent should not be performed until the dog is stable, but monitoring for acute gastric distention is imperative.)

INSTRUMENTED ASSESSMENT

Oxygenation and ventilation status are ideally evaluated using an arterial blood gas, and pulse oximetry can provide some information relative to oxygenation. Pulse oximeter probes are best applied to the tongue, ear, lips, toe-web, prepuce, or vulva of the canine patient.

Thoracic injuries frequently result in shock. Treatment for shock should be initiated as soon as it is identified.^{10,11,15} Treatment of shock in the canine patient was covered in the second article in this series.¹⁰ Pain secondary to thoracic trauma may restrict the canine patients' respiratory function and appropriate pain treatment should always be provided.^{4,6,7,8,10} Treatment of significant blood loss (HCT < 15) requires transfusion of either a canine artificial blood substitute (Oxyglobin)^{10,16} or whole canine blood.^{10,16} (**Editor's Note:** *Many working dogs' hematocrits are higher than the normal canine. Treatment should be based upon clinical signs and hemodynamic stability versus a strict number.*) It is important to remember that Oxyglobin provides oxygen carrying capacity and osmotic stability, but does not provide normal blood proteins and clotting factors.¹⁶ (**Editorial Note:** *Oxyglobin is approved for use in dogs by the FDA and it is commonly used in veterinary ERs around the country. However, currently very limited supplies exist and it is important to note that there are conflicting opinions/articles. There may be significant hemodynamic effects – potentially adverse – with the use of hemoglobin solutions causing consequences to later diagnostics until the hemoglobin is cleared. However, it is the author's professional experience Oxyglobin is a valuable tool [see references].*)

THORACIC TRAUMA SUMMARY

Flail chest, pulmonary contusion, pneumothorax, open chest wounds, hemothorax, and diaphragmatic rupture are common secondary to thoracic trauma.^{11,12} Thoracic wounds should be explored and wounds that penetrate the thoracic cavity warrant a thoracotomy to explore the chest for further injury. Pain management including injectable analgesics as well as local anesthetic blocks are important aspects of treatment of thoracic injury. Management of thoracic injury involves treatment for shock and assessment of oxygenation and ventilation. Intubation and manual ventilation should be performed when respiratory distress persists despite oxygen supplementation. Mechanical ventilation until surgical intervention is available may be required in cases of oxygenation or ventilatory failure.^{9,11,12,14}

ABDOMINAL TRAUMA

The principles surrounding the initial approach to the patient with abdominal trauma are similar to those in a patient that has sustained any form of trauma. The clinician should perform a general overall physical that initially avoids the abdomen to avoid eliciting significant pain or vagal response.¹⁸ Rapid assessment of the cardiovascular and respiratory systems should be performed, and the patient should be evaluated for clinical signs of shock.¹¹ If physical examination findings are supportive of shock (e.g., tachycardia, pale mucous membranes, poor pulse quality), then a large bore intravenous catheter should be placed and fluid therapy should be initiated promptly as described previously.^{4,10,11,18}

Once any necessary treatment for shock has been initiated, then a second, more thorough physical examination should be performed. The examination of the abdomen itself should include visual inspection, auscultation, percussion, ballottement, superficial and deep palpation, and digital rectal examination.¹⁸ In some instances the presence of abdominal trauma may be easily identified with physical examination alone (especially when external wounds are present).

The presence of wounds or bruising over the abdomen should alert the care provider to the potential for internal injuries. Abdominal distension may indicate the presence of a hemo-abdomen or uro-abdomen or gastric dilatation and volvulus. Abdominal pain, while a non-specific finding, may be an early indicator of abdominal trauma. Bruising or swelling in the caudal inguinal area can be associated with urinary tract rupture. A soft fluctuant swelling under the skin may be indicative of a body wall hernia.

GUNSHOT WOUNDS

Injuries associated with gunshot wounds frequently involve penetrating trauma to the abdomen. Physical examination findings often include bruising as well as ballistic entry and sometimes exit wounds. It is often necessary to shave the hair over the abdomen to identify small ballistic wounds.⁹

In the event a wound is identified that penetrates the abdomen, then an exploratory laparotomy should be performed to rule out injuries to internal organs. The potential for internal injuries resulting from ballistic wounds should not be underestimated, and include punctured bowel, avulsed renal vessels, and urinary tract rupture. However, in a field environment, initial treatment should consist of irrigation and replacement of any eviscerated bowel or other organs, followed by bandaging of the wound. Antibiotic therapy is indicated in all dogs that have sustained gunshot wounds.^{9,18,19}

BLAST INJURY

Blast injuries are the second most common cause of thoracoabdominal trauma in the working canine⁹ and blast injury to the abdomen results in wounds similar to that of vehicular trauma in the general canine population. Wounds sustained from these compressive force injuries are often extensive and extend into the inguinal region.^{18,19}

In all cases where the clinician develops evidence of abdominal trauma, once cardiovascular stability has been achieved, the patient should undergo abdominocentesis, or exploratory laparotomy. Injury to the biliary tree, gallbladder, or liver can result in the expression of bile into the abdomen. Injury to the kidneys, ureters, bladder, prostate, or urethra can result in urine in the abdomen. The presence of bile or urine in the abdominal cavity causes an inflammatory reaction leading to peritonitis, which may or may not be septic. Injury to the gastrointestinal tract can result in feces and bacteria in the abdomen and septic peritonitis. When abdominocentesis reveals evidence of inflammation, bile, urine, feces, or bacteria, an exploratory laparotomy is indicated. Surgical management is warranted in the patient with bile or urine peritonitis.^{18,19}

HEMOABDOMEN

Injury to any abdominal organ can result in hemoabdomen.¹⁹ Significant abdominal bleeding will result in worsening cardiovascular status over time despite appropriate treatment of shock. When large volumes of blood enter the abdomen, the abdomen may distend and become firm on palpation in every quadrant. Abdominal distension, combined with worsening cardiovascular status, may require the need for immediate emergency exploratory laparotomy. (*Editor's Note: Abdominocentesis is a quick technique to help diagnose and differentiate the causes of a fluid wave.*)

Canine patients that experience vehicular or blast trauma should undergo portable ultrasound or radiographic examination of the thorax and abdomen as soon as possible and in advance of exploratory laparotomy where possible. (*Editor's Note: It is worth reiterating the need for stabilization prior to any anesthetic event.*)

Other uncommon sequelae of abdominal trauma include infarction of renal, splenic, or other vessels, and avulsion of mesenteric vessels. Infarction of major vessels, for example the splenic vein, may lead to necrosis and septic peritonitis. Avulsion of mesenteric vessels, while not causing substantial blood loss, leads to segmental bowel necrosis three to seven days following a traumatic event. Since these injuries may not be recognized immediately, the development of lethargy, anorexia, vomiting, or fever a few days or a few weeks

following trauma warrants re-evaluation of the patient, or reconsideration of abdominal trauma in a canine patient with history of recent traumatic wounds.^{11,19}

Canines with abdominal trauma should be evaluated for thoracic trauma. Penetrating injury to either body cavity should be a clinical indication to monitor the other major body cavity, as well as the cardiovascular, pulmonary, and central nervous system very closely until the patient fully recovers.

ABDOMINAL TRAUMA SUMMARY

Immediate assessment and stabilization of major body systems including the cardiovascular system, the respiratory system, and the central nervous system should be performed in the patient with abdominal trauma.^{18,19} Any wound located over the abdominal area should be explored, and an exploratory laparotomy should be performed in any patient with a wound that penetrates into the abdominal cavity. However, medical management of the patient with a traumatic abdominal injury is often possible and should be performed initially until professional veterinary care can be provided. Surgical exploration should not be performed until cardiovascular stability and adequate perfusion has been restored, or if hemodynamic instability persists despite aggressive efforts at resuscitation.^{18,19}

Abdominal injuries secondary to traumatic events can be manifested immediately or several days following trauma. Lethargy, inappetence, or vomiting three to seven days following a traumatic event should alert the clinician to the possibility of internal injuries including devitalized bowel or bile duct rupture and should be evaluated immediately.¹⁹

SUMMARY

Thoracic and abdominal injuries are among the most common causes of morbidity and mortality in military working dogs and police dogs.^{4,6,7,9} The distribution of wounds is different in the canine patient population than in the human patient population, but the assessment procedures and medical and surgical management of these wounds are very similar.⁹ Although gunshot wounds and blast injuries are responsible for the majority of thoracic and abdominal trauma, military and other tactical medical personnel are well trained in the provision of medical care to these types of injuries in the operational environment.^{4,9} By familiarizing themselves with the basic principles of veterinary medical and surgical care of working canines provided in this series of articles, human medical providers can provide appropriate and timely pre-veterinary hospital medical care to the canine patient.

Table 1. Canine Field Care Card

Parameter	At Rest	Exercise	Drug Dose	Standard Dose	CV Shock Dose
Temp.	100.5-101.5	101.0-104	Crystalloids	2.0-3 L / 24hr	10-50 ml/kg/hr * (Accepted shock dose of crystalloids is 90 ml/kg/hr, given in 1/4 dose boluses, to effect)
Heart Rate	60-75	75-130	Hespan (6% hetastarch)	n/a	5-10 ml/kg, up to 20 ml/kg/day
Resp. Rate	10-20	30-panting	Morphine	0.5 - 2 mg/kg IM	n/a
Mucus mm	Pink	Bright pink	Diphenhydramine	1 mg/lb q 6-8 hrs	n/a
CRT	1-2 secs	1 sec	Diazepam	0.1-0.15 mg/lb slow IV	Seizures: 0.5 mg/lb IV bolus to effect
Pulses	Moderate	Bounding	Fentanyl	0.004-0.01+ mg/kg (4-10 mcg/kg) IV bolus and then 0.001-0.004 mg/kg/100 (4-10 mcg/kg/hour) constant rate IV infusion	n/a
Heart Sounds	Behind left shoulder	Sinus arrhythmia except after exercise	Water	Maintenance 2.0-3 L / 24hr	Exercise 5-15 L / 24hr
Resp Sounds	Caudal 1/3 of thorax	Louder than human	Food	Maintenance 4-6 cups dry / 24hr	Exercise 8cups / 24hr

Table 1 contains normal physiological parameters and physical exam findings for working canines in the weight range of 85 to 110 lbs. **Editor's Note:** The majority of MWDs are in the 65-85 pound weight range. Female Malinois are often 5-8 pounds lighter/smaller. The drug doses denoted with an asterisk are from the "Shock" article in the textbook "The 5-Minute Veterinary Consult."²² Other values are condensed and edited from articles referenced herein and are consistent with those used by this author in private practice on working canines.^{4,8,15,20,21,23,24} This card may be photocopied and laminated for the use of individual JSOM subscribers.

REFERENCES

- Miles, D. (2004, Sep. 3), Military working dogs protect forces, bases during terror war. *Armed Forces Press Service*. Retrieved July 1, 2008 from Defense Link website. Website: (<http://www.defenselink.mil/news/newsarticle.aspx?id=25393>).
- Barrett, K. (2006, Mar. 10), The nose knows – military working dogs complete security forces mission. *Air Force Link*. Retrieved July 1, 20-8 from AF Link website. Website: (<http://www.af.mil/news/story.asp?storyID=123017117&page=1>).
- Dillon, T. (2005, Sep. 16). Military working dogs save many lives - from locating improvised explosive devices to identifying weapons caches, these trained dogs assist troops with Operation Enduring Freedom. *U.S. Department of Defense News About the War on Terrorism*. Retrieved from Defend America Website July 1, 2008. Website: (<http://www.defendamerica.mil/articles/sep2005/a0916051a1.html>).
- Vogelsang, Robert DVM, MS (2007). Care of the military working dog by medical providers. *Journal of Special Operations Medicine*; 7(2)(Spring):33-47.
- U.S. Army Veterinary Services Homepage. Retrieved July 1, 2008. Website: (<http://www.veterinaryservice.army.mil/animal.html>).
- Baker, MAJ Janice and Truesdale, CPT Christine (2007). Gunshot wounds in military working dogs. *Journal of Special Operations Medicine*; 8(1)(Winter):120-121.
- Slensky, Kimberly A. DVM; Kenneth J. Drobotz, DVM, MS, DACVECC, DACVIM; Amanda B. Downend, BA; and Cynthia M. Otto, DVM, PhD, DACVECC. Deployment morbidity among search-and-rescue dogs used after the September 11, 2001, terrorist attacks. *Journal of the American Veterinary Medical Association* 225(6) 868. Downloaded from AVMA website on July 1, 2008. Website: (www.avma.org/avma_collections/disaster/javma_225_6_868.pdf).

8. Taylor, Wesley M. (2008). Canine tactical field care: Part One – The physical examination and medical assessment. *Journal of Special Operations Medicine*; 8(3)(Summer 08):44-60.
9. Baker, MAJ Janice L. et al. (2009). Overview of combat trauma in Military Working Dogs in Iraq and Afghanistan. *Journal of Special Operations Medicine*; 9(2) 105-108.
10. Taylor, Wesley M. (2009). Canine tactical field care: Part Two – Massive hemorrhage control and physiologic stabilization of the volume depleted, shock-affected, or heatstroke-affected canine. *Journal of Special Operations Medicine*; 9 (2) 13-21
11. De Laforcade , Armelle. Management of thoracic trauma proceedings of the TUFTS ANIMAL EXPO 2002. Retrieved January 1, 2010 from Veterinary Information Network website: (<http://www.vin.com/Members/Proceedings/Proceedings.plx?CID=tufts2002&PID=pr01953&O=VIN>).
12. Hulse, Donald A. and Ann L. Johnson. (1997). Surgery of the lower respiratory system: Pleural cavity and diaphragm. In Theresa Welch Fossum Ed. *Small Animal Surgery*. St. Louis, MO, Mosby, p. 675-704.
13. Committee on Tactical Combat Casualty Care (2003). Tactical combat casualty care: Prehospital care in the tactical environment. Retrieved from Special Operations Medical Association Website April 3, 2009. Website: (http://somaonline.org/final_draft_phtls_manual.pdf).
14. Fossum, Theresa Welch. (1997). Surgery of the lower respiratory system: Lungs and thoracic wall. In Theresa Welch Fossum Ed. *Small Animal Surgery*; St. Louis, MO, Mosby, p. 649-674.
15. Haskins, Steve C. (2000). Therapy for shock. In John Bonagura Ed. *Kirk's Current Veterinary Therapy XIII Small Animal Practice*. Philadelphia, WB Saunders Co. p. 140-147.
16. Rentko, Virginia. (2000). Practical use of a blood substitute. In John Bonagura Ed. *Kirk's Current Veterinary Therapy XIII Small Animal Practice*. Philadelphia, WB Saunders Co. p. 424-427.
17. Giger, Urs (2000). Blood typing and crossmatching to ensure compatible transfusions. In John Bonagura Ed. *Kirk's Current Veterinary Therapy XIII Small Animal Practice*. Philadelphia, WB Saunders Co. p. 140-147.
18. Mann, F.A. (2000). Acute abdomen: Evaluation and emergency treatment. In John Bonagura Ed. *Kirk's Current Veterinary Therapy XIII Small Animal Practice*. Philadelphia, WB Saunders Co. 2000, p. 160-164.
19. De Laforcade, Armelle. Management of abdominal trauma. proceedings of the TUFTS ANIMAL EXPO 2002. Retrieved January 1, 2010 from Veterinary Information Network website: (<http://www.vin.com/Members/Proceedings/Proceedings.plx?CID=tufts2002&PID=pr01952&O=VIN>).
20. Gillick, Avery, BSc, DVM, Dipl. Med, MSc. Emergency care of the police dog. Retrieved July 1, 2008 from United States Police Canine Association website. Website: (www.uspcak9.com/medical/emergency.pdf). (The normal values referenced here are consistent with this author's experience).
21. DiBartola, S.P. (1992). Introduction to fluid therapy. In DiBartola SP Ed. *Fluid therapy in Small Animal Practice*. Philadelphia WB Saunders Co. p. 321.
22. Dhupa, Nishi. (1997). Shock. In Larry P. Tilley and Francis W.K. Smith Jr. Eds. *The 5 Minute Veterinary Consult – Canine and Feline*. (p. 150-151). Baltimore, MD: Williams and Wilkins.
23. Buecheler, Jorg. (1997). Heatstroke and hyperthermia. In Larry P. Tilley and Francis W.K. Smith Jr. Eds. *The 5 Minute Veterinary Consult – Canine and Feline*. (p. 640-641). Baltimore, MD: Williams and Wilkins.
24. Plumb DC. (2005). Plumb's Veterinary Drug Handbook. 5th Edition. PharmaVet, Inc., Stockholm, WI.



Dr. Wesley M. Taylor holds degrees from Rice University (BA 1988) and Texas A&M University (DVM) and is a Diplomate of The American College of Laboratory Animal Medicine. He served as the Assistant Director of Laboratory Animal Medicine at the University of Mississippi Medical Center and as the Chairman of Primate Medicine and Surgery at the New England National Primate Research Center, Harvard Medical School. During this time, he also served as an officer in the Mississippi Air National Guard. For the last 10 years, Dr. Taylor has been in private practice in the north Texas area, where he practices general and emergency veterinary medicine and surgery, and serves as a veterinary consultant at the Texas Research and Education Institute (TREI) and the University of North Texas Medical Center. Dr. Taylor has over 16 years of experience with working canines and lectures frequently to law enforcement groups on emergency medicine and surgery of the canine officer, and he serves as a veterinary consultant to several Texas area law enforcement agencies. Dr. Taylor serves as veterinarian and instructor in TCCC training courses for the Asymmetric Combat Institute, Advanced Medical Training and the Operational Medicine Fund of the Presbyterian Healthcare Foundation.